



Comparison among Different Methods in Treatment of Anal Fissures

Mohanad E. Al-Sherify¹, Ali Mohammed Hussein AlMahdawi²
Amjed H. Abbas³

(¹) Department of general surgery, Almussayb hospital, Babil health directorate, Iraq ministry of health.

malsherifynamealsn@gmail.com

(²) Specialist Surgeon .Alexandria General Hospital. Babil health directorate.

dr.alialmahdawi@yahoo.com

(³) Environmental Research and Studies Center, University of Babylon, Babylon,

Iraq.amjedhassan982@yahoo.com

*Corresponding author [Email: amjedhassan982@yahoo.com](mailto:amjedhassan982@yahoo.com)

Accepted: 29/3/2026

Published: 31/3/2026

ABSTRACT

Background: Anal fissures represent one of the common diseases that affect the anorectal area. Patients present with painful tears in this area that finally result in chronic discomfort and pain. Multiple surgical procedures were applied in the treatment of chronic anal fissures, but the optimal technique remains unclear.

Aims of the study: This study aimed to perform an assessment of three surgical techniques used in the treatment of chronic anal fissures regarding fissure healing, pain remission, and related complications.

Patients and methods: The study was performed in the period from November 2023 to April 2025, it consists of 180 patients with chronic anal fissures. Random distribution of patients into three treatment groups: Group A (Topical Nifedipine), Group B (Laser Therapy), and Group C (Lateral Internal Sphincterotomy). These procedures were evaluated using three methods of assessment: pain remission, fissure healing, and complications at period intervals of one, two, four, and six weeks post-treatment in addition to long-term follow-up through six and twelve months intervals.

Results: Laser therapy represented the most effective treatment procedure. In this procedure, the pain remission ratio was 96.5% then lateral internal sphincterotomy 90.7% and lastly topical Nifedipine 75%. The highest rate of fissure healing after six weeks was performed in Laser therapy (the ratio was 94.8% while surgery was 82.9% and Nifedipine 67.3%). The fewest complications were found in laser method with a low recurrence rate of 3.6%.

Conclusion: The study revealed that laser therapy technique represents the most effective and safest method of treatment for chronic anal fissures because it had rapid pain relief, rapid healing and few complications.

Keywords: Chronic anal fissure, laser therapy, lateral internal sphincterotomy, nifedipine.



INTRODUCTION

The chronic anal fissures are small tears in longitudinal lines in the lining area of the anus called the anoderm. These fissures usually occur in the posterior midline and sometimes in the anterior area of the anal canal [1]. They are classified into two types depending on their duration and response to treatment: Type 1 are acute fissures that have a duration of less than six weeks and heal with conservative treatments. Type 2 are chronic fissures that persist more than 6 months and are usually complicated by fibrosis, sentinel tags, and hypertrophic papillae[2,3].

Anal fissures are common conditions that usually affect 1 in 10 people during their life [4]. They mostly occur in adults aged between 20 and 40 years and affect both males and females in equal percentages [5]. The risk factors for this condition are constipation, diarrhea or underlying medical diseases like Crohn's disease [6]. The clinical features of the disease include sharp tearing pain lasting for minutes to hours and related to defecation [7,8]. The chronic fissures are characterized by the presence of tears or sentinel tags of hypertrophic papillae [9,10]. The diagnosis of fissures is usually clinical depending on history and clinical examination [11,12]. The treatment is either medical or surgical depending on the severity and duration of the condition as follows:

Conservative treatments which represent the first line of treatment and include dietary modifications like increased fluid intake, increased amount of fiber in diet, increased water intake which reduce constipation and straining [13]. **Topical therapy** which can be used in acute and chronic fissures such as Glyceryl trinitrate (GTN) ointment that help in reduction of pressure of the anal sphincter and Calcium channel blockers, such as nifedipine and diltiazem, causes relaxation of the internal anal sphincter with fewer side effects [14].

Surgical method which is used in two conditions: 1. If conservative or topical therapy failed 2. Chronic or complicated fissures. The gold procedure is **lateral internal sphincterotomy (LIS)** which includes removal of a portion of internal anal sphincter with a high success rate (95%) but has a risk of fecal incontinence [15]. Other methods of treatment is **Minimally Invasive Techniques like laser therapy and pneumatic dilation** that are especially used in those patients with high risk for incontinence [16]. The last method is **combined treatment** that involve combination of more than one type of treatment such as a combination of Botox injection with topical agents like GTN or combining pneumatic dilation with conservative treatment [17]. This study aimed to compare the three following methods of treatment in chronic anal fissures: topical Nifedipine ointment, laser therapy, and LIS surgery regarding pain remission, healing rate, and complications.

PATIENTS AND METHODS

The study was performed in Al-Hussain Teaching Hospital, Safer Al-Hussain Hospital, and various private clinics in the period from November 2023 to April 2025. It involved 180 patients with chronic anal fissures who were distributed into one of three treatment modalities: topical nifedipine ointment, laser therapy, and LIS surgery. Each group involved 60 patients. The groups were well-matched regarding age, gender and other demographic characteristics. Inclusion criteria include patients with chronic anal fissure, fissure fibrosis, or presence of sentinel pile. Exclusion criteria include uncooperative patients, pregnancy or

Table (2) and figure (1) reveal that laser treatment (Group B) shows the highest and quickest pain remission rates across all follow-up periods, significantly outperforming Nifedipine (Group A) and Surgery (Group C). By the sixth week, pain remission reached 96.7% in Group B, compared to 91.7% in Group C and 75% in Group A, with the largest differences observed in the earlier weeks.

Table 2: Pain Remission Over Time

Follow-Up Interval	Group A (Nifedipine) (No=60)	Group B (Laser) (No=60)	Group C (Surgery) (No=60)	P-Value (A vs B)	P-Value (A vs C)	P-Value (B vs C)
1st Week	20 (33.3%)	45 (75%)	35 (58.3%)	0.001	0.020	0.050
2nd Week	30 (50%)	50 (83.3%)	45 (75%)	0.010	0.050	0.300
4th Week	40 (66.7%)	55 (91.7%)	50 (83.3%)	0.020	0.070	0.150
6th Week	45 (75%)	58 (96.7%)	55 (91.7%)	0.030	0.100	0.200

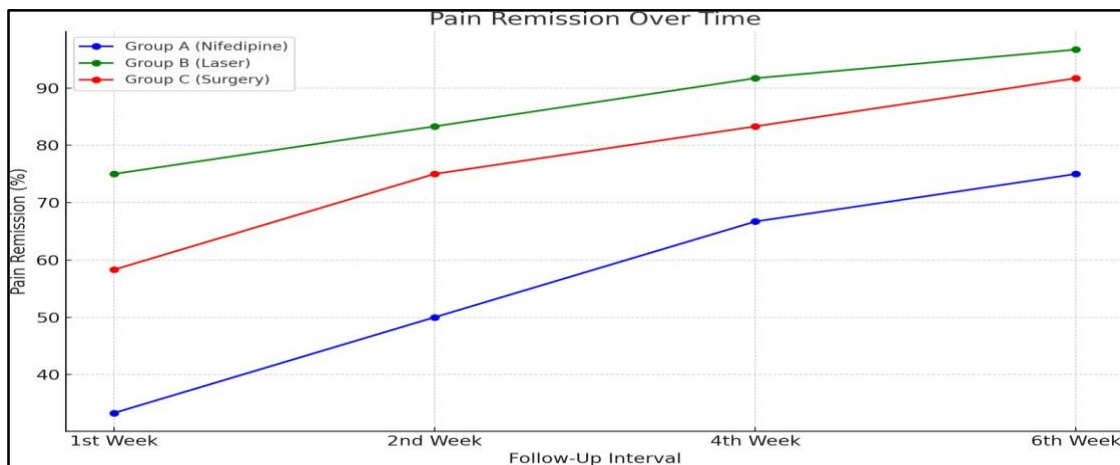


Figure 1 Pain Remission Over Time

Fissure healing is most rapid and pronounced in the Laser group (Group B), achieving a 96.7% healing rate by the sixth week, significantly higher than Nifedipine (66.7%) and Surgery (83.3%). Laser consistently leads to faster and more complete healing than other treatments as illustrated in table (3) and figure (2).

Table 3: Fissure Healing Over Time

Follow-Up Interval	Group A (Nifedipine) (No=60)	Group B (Laser) (No=60)	Group C (Surgery) (No=60)	P-Value (A vs B)	P-Value (A vs C)	P-Value (B vs C)
1st Week	0 (0%)	20 (33.3%)	15 (25%)	0.001	0.010	0.300
2nd Week	10 (16.7%)	40 (66.7%)	30 (50%)	0.001	0.020	0.050
4th Week	30 (50%)	55 (91.7%)	45 (75%)	0.010	0.050	0.070
6th Week	40 (66.7%)	58 (96.7%)	50 (83.3%)	0.020	0.050	0.150

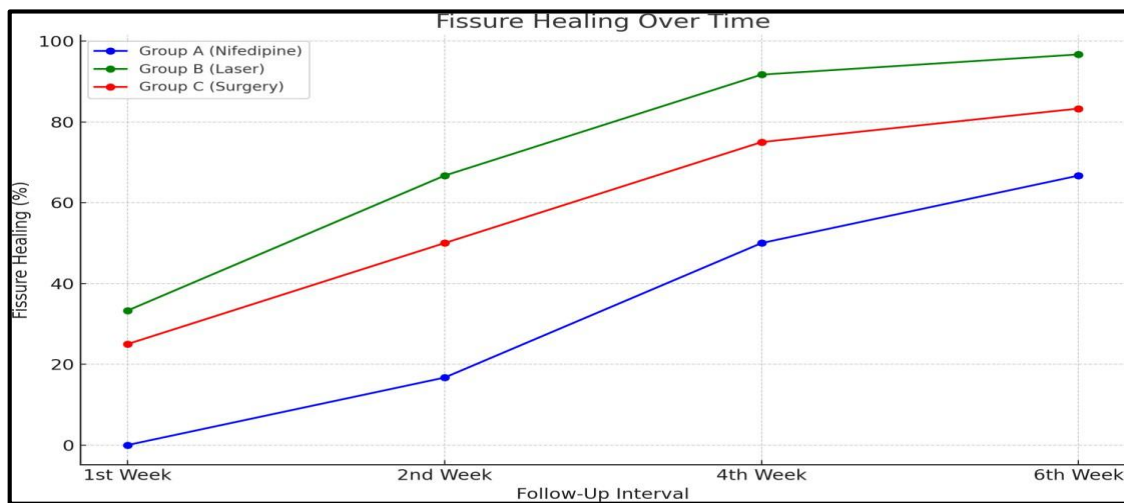


Figure 2 Fissure Healing Over Time

Regarding the adverse effects of treatments, table (4) and figure (3) show that Nifedipine treatment method (Group A) has the highest incidence of adverse effects, including headaches (30%) and a higher recurrence rate (20%). Laser therapy (Group B) shows the fewest complications, with no headaches and the lowest recurrence rate (3.3%), making it the safest and most effective option among the three treatments.



preferable method for treatment of anal fissures. This result is consistent with a study performed by [14, 16], which found that postoperative pain was less than in a lateral internal sphincterotomy. In Nifedipine group, there is a slower response for healing that makes it less beneficial in severe cases. The data in Table 3 reveals that laser therapy is the most effective treatment for promoting fissure healing over time, with a significantly higher percentage of patients experiencing complete healing by the sixth week compared to those treated with Nifedipine or surgery. Laser therapy achieves rapid and extensive healing, with 96.7% of patients showing complete recovery by the end of the study period. This is consistent with the finding of [16]. Laser therapy enhances blood flow to the affected area, which not only reduces discomfort but also accelerates the healing process by ensuring that more oxygen and nutrients reach the damaged tissues. This increased circulation supports quicker tissue regeneration and recovery [17]. In contrast, Nifedipine shows a slower and less effective healing process, with only 66.7% of patients achieving full healing within the same timeframe. Surgery, while more effective than Nifedipine, still lags behind laser therapy, with 83.3% of patients experiencing complete healing by the sixth week. Alam 2021 reported similar findings with healing rates in laser therapy higher over time than surgery [18]. However, no previous study compared the three methods in terms of healing, pain or side effects and complications. The Nifedipine group has a notably high incidence of headaches (30%), which was not reported in the laser therapy or surgery groups. This side effect is consistent with the known vasodilatory effects of Nifedipine, which can lead to systemic side effects such as headaches [19]. Transient incontinence was reported in 8.3% of patients in the Nifedipine group and 5% in the surgery group, but not in the laser therapy group. This is consistent with the findings of [16]. The surgery involves cutting a portion of the internal anal sphincter to reduce pressure, but the resulting muscle damage can lead to fecal incontinence. Although most cases are transient, some patients reported chronic incontinence[20]. The lower recurrence rates observed in the laser therapy group are particularly noteworthy. Recurrence of anal fissures is a common concern, especially following surgical interventions. Liang et al. reported a 5% risk of recurrence after lateral internal sphincterotomy, which aligns with the present study [17]. The ability of laser therapy to maintain low recurrence rates may be attributed to its precise action on the sphincter muscle, effectively reducing sphincter pressure while preserving sphincter integrity [19 and 21]. A study by Talaat et al. in 2022 on the effectiveness of laser therapy on anal conditions showed a zero recurrence rate in chronic anal fissure [16]. Another study by Asefa et al. on 200 patients suffering from chronic anal fissures showed no recurrence after treatment with laser therapy [4]. The follow-up period might not be long enough to capture long-term outcomes such as late recurrence or delayed complications, which are important in chronic conditions like anal fissures. Moreover, potential variations in treatment administration and practitioner skill levels could introduce variability in the outcomes observed across the different treatment methods.



CONCLUSIONS

From the results, we conclude that laser therapy is the most effective method for treatment of chronic anal fissures because it offers fast pain relief and healing with few complications. The surgery method of treatment has more risks and complications while the last method which is Nifedipine method is less effective and associated with adverse effects.

Ethics approval

The authors of this study declare that their work including questionnaire and procedure followed the regulations of the suitable clinical research ethics and with the principles of the Code of Ethics of the World Medical Association (Declaration of Helsinki, 2013).

Conflict of interest.

There are no conflicts of interest.

References

1. JZ, Jin; S, Bhat; B, Park; MO, Hardy; H, Unasa; M, Mauiliu-Wallis; AG, Hill . A systematic review and network meta-analysis comparing treatments for anal fissure. *Surgery*. 2022 Jul;172(1):41-52. doi: 10.1016/j.surg.2021.11.030. Epub 2022 Jan 5. PMID: 34998619.
2. Z, Asefa; AF, Awedew. *Sci Rep*. 2023 Nov 28;13(1):20957. doi: 10.1038/s41598-023-48286-z .Comparing closed versus open lateral internal sphincterotomy for management of chronic anal fissure: systematic review and meta-analysis of randomised control trials.
3. A, Tanveer; S, Arshad; N, Fakhri; DA, Farooq; A, Afyouni; A, Kamran; M. Imran. *Ann Med Surg (Lond)*. 2023 Dec 8;86(2):975-985. doi: 10.1097/MS9.0000000000001593. Collection 2024 Feb.
4. Z., Asefa; A.F, Awedew. Comparing closed versus open lateral internal sphincterotomy for management of chronic anal fissure: systematic review and meta-analysis of randomised control trials. *Sci Rep* 13, 20957 (2023).
- 5.A. Picciariello, R. Tutino, U. Grossi. Temporal trends and treatment patterns in anal fissure management: insights from a multicenter study in Italy. *Techniques in Coloproctology* (2024).
6. T. AcarN. Acar+5 authors M. Hacıyanlı. Comparative efficacy of medical treatment versus surgical sphincterotomy in the treatment of chronic anal fissure. *Nigerian journal of clinical practice*.2020.
- 7.R, Tutino; C, Nigro; F, Paternostro; R, Federico; G , Lo Secco; et al. Fissurectomy versus lateral internal sphincterotomy in the treatment of chronic anal fissures: no advantages in terms of post-operative incontinence. *Tech Coloproctol*. 2023;27(10):885-9.
8. A, Balla ; F, Saraceno; M, Shalaby; G, Gallo; S, Di Saverio; et al. Surgeons' practice and preferences for the anal fissure treatment: results from an international survey. *Updates in Surgery*. 2023;75.
9. P, Ciesielski; M Kołodziejczak. Treatment of anal fissure-combining different therapeutic approaches. 2021.
10. I, Pinski; D, Czeiger; D, Lichtman; A, Reshef . The Long-term Effect of Standardized Anal Dilatation for Chronic Anal Fissure on Anal Continence. *Ann Coloproctol*. 2021;37(2):115-9.
11. TM, Liska; AM, Kolen . The role of physical activity in cancer survivors' quality of life. *Health Qual Life Outcomes*. 2020;18(1):197.
12. AH, Elfallal; M, Fathy; SA, Elbaz; SH, Emile . Comprehensive literature review of the applications



- of surgical laser in benign anal conditions. *Lasers in Medical Science*. 2022;37(7):2775-89.
13. S, Nayar; M, Joshi; Q, Jamal; S, Khurana. A review of recent advances in the surgical management of anal fissures. *International Surgery Journal*. 2023;10(7):1262-7.
 14. AR, Sabek; IH, Bayan; MI, Monier . Comparing Outcomes of Lateral Internal Sphincterotomy and Laser sphincterolysis in the Management of Chronic Anal Fissure. *Al-Azhar International Medical Journal*. 2024;5(5):50.
 15. MN, Esfahani; G, Madani; S, Madhkhan . A novel method of anal fissure laser surgery: a pilot study. *Lasers in medical science*. 2015;30(6):1711-7.
 16. PN, Maurice; ARM, Amin, T, Habeeb; YA, Orban . Comparing Outcomes of Lateral Internal Sphincterotomy, Botulinum Toxin Injection and Laser Therapy in the Management of Chronic Anal Fissure. *The Egyptian Journal of Hospital Medicine*. 2023;90(2):2482-7.
 17. G, Hall; BR, Kann . Anal Fissure. *Anorectal Disease: Contemporary Management*. 2016:95-126.
 18. A, Alam. Laser surgery for treatment of haemorrhoid and anal fissure and its outcome. *Sch J App Med Sci*. 2021;5:663-9.
 19. Y, Alahamd; HAI, Swehli; A, Rahhal; S, Sardar; MAM, Elhassan; et al. Calcium channel blockers. *New Insight into Cerebrovascular Diseases-An Updated Comprehensive Review*: IntechOpen; 2020.
 20. F, Al-thoubaity . Safety and efficacy of the treatment of chronic anal fissure by lateral internal sphincterotomy: A retrospective cohort study. *Annals of Medicine and Surgery*. 2020;57:291-4.
 21. M, Talaat; A, Hazem; Abdel-Hady; MM, Elsheikh. Outcomes of Diode Laser in Treatment of Common Anal Surgical Lesions (Haemorrhoids, Chronic Fissure and Fistula): A Prospective Study. *Asian Journal of Research in Surgery*. 2022;7(3):21-40.